

Brian D. Stapp, D.D.S., P.A. *
Dana M. Brotherton, D.D.S., M.D.
* Diplomate, American Board of Oral & Maxillofacial Surgery
Practice Limited to Oral and Maxillofacial Surgery

May 14, 2004

To Whom It May Concern:

Joan Butzke is a fellow patient of ours and she asked me to write a note explaining her current situation.

She had an extraction done approximately one year ago in the right maxilla and subsequently did not heal well. She had significant amounts of necrotic bone that developed and this was debrided over a six-month period.

She has now developed another area in the left maxilla between teeth numbers 14 and 15. This bone has become necrotic and developed a sinus tract to her left maxillary sinus that constantly drains. The only procedure she had in this area was sinus surgery two months prior by an ENT surgeon in this area.

These areas are probably due to the bisphosphonate therapy. See enclosed article. This letter is just to inform of her current intraoral situation.

If I can be of any assistance, please contact me at (281)-933-9950.

Sincerely,

Brian D. Stapp, DDS

Osteonecrosis of the Jaws Associated With the Use of Bisphosphonates: A Review of 63 Cases

Salvatore L. Ruggiero, DMD, MD,* Bhoomi Mebrotra, MBBS,†
Tracey J. Rosenberg, DMD, MD,‡
and Stephen L. Engroff, DDS, MD§

Purpose: Bisphosphonates are widely used in the management of metastatic disease to the bone and in the treatment of osteoporosis. We were struck in the past 3 years with a cluster of patients with necrotic lesions in the jaw who shared 1 common clinical feature, that they had all received chronic bisphosphonate therapy. The necrosis that was detected was otherwise typical of osteoradionecrosis, an entity that we rarely encountered at our center, with less than 2 patients presenting with a similar manifestation per year.

Patients and Methods: We performed a retrospective chart review of patients who presented to our Oral Surgery service between February 2001 and November 2003 with the diagnosis of refractory osteomyelitis and a history of chronic bisphosphonate therapy.

Results: Sixty-three patients have been identified with such a diagnosis. Fifty-six patients had received intravenous bisphosphonates for at least 1 year and 7 patients were on chronic oral bisphosphonate therapy. The typical presenting lesions were either a nonhealing extraction socket or an exposed jawbone; both were refractory to conservative debridement and antibiotic therapy. Biopsy of these lesions showed no evidence of metastatic disease. The majority of these patients required surgical procedures to remove the involved bone.

Conclusions: In view of the current trend of increasing and widespread use of chronic bisphosphonate therapy, our observation of an associated risk of osteonecrosis of the jaw should alert practitioners to monitor for this previously unrecognized potential complication. An early diagnosis might prevent or reduce the morbidity resulting from advanced destructive lesions of the jaw bone.

© 2004 American Association of Oral and Maxillofacial Surgeons
J Oral Maxillofac Surg 62:527-534, 2004

Cancer patients with metastatic bone lesions often present with a multitude of complications that in-

clude pain, pathologic fracture, spinal cord compression, and hypercalcemia.¹ Bone metastases result in excess activation of osteoclasts mediated by a variety of cytokines produced by tumor cells.² Bisphosphonates are nonmetabolized analogues of pyrophosphate that are capable of localizing to bone and inhibiting osteoclastic function. Bisphosphonates bind avidly to exposed bone mineral around resorbing osteoclasts, resulting in very high levels of bisphosphonate in the resorption lacunae. Because bisphosphonates are not metabolized, these high concentrations are maintained within bone for long periods of time. Bisphosphonates are then internalized by the osteoclast, causing disruption of osteoclast-mediated bone resorption. Although exact mechanism of this bisphosphonate-mediated osteoclast inhibition has not been completely elucidated, it has been established that these compounds affect bone turnover at

*Chief, Division of Oral and Maxillofacial Surgery, Long Island Jewish Medical Center, New Hyde Park, NY.

†Attending, Division of Hematology and Oncology, Long Island Jewish Medical Center, New Hyde Park, NY.

‡Former Chief Resident, Division of Oral and Maxillofacial Surgery, Long Island Jewish Medical Center, New Hyde Park, NY.

§Fellow, Department of Dentistry and Oral and Maxillofacial Surgery, University of Maryland Medical Systems, Baltimore, MD.

Address correspondence and reprint requests to Dr Ruggiero: Division of Oral and Maxillofacial Surgery, Long Island Jewish Medical Center, New Hyde Park, NY 11040; e-mail: ruggiero@lij.edu

© 2004 American Association of Oral and Maxillofacial Surgeons
0278-2391/04/6205-0077\$30.00/0

doi:10.1016/j.joms.2004.02.004

various levels.³ At the tissue level, bisphosphonates will inhibit bone resorption and decrease bone turnover as assessed by biochemical markers. The degree to which these compounds will also alter bone formation is related to their effects on bone turnover, which is closely coupled to bone formation. On a cellular level, the bisphosphonates are clearly targeting the osteoclasts and may inhibit their function in several ways: 1) inhibition of osteoclast recruitment,⁴ 2) diminishing the osteoclast life span,⁵ and 3) inhibition of osteoclastic activity at the bone surface.⁶ At a molecular level, it has been postulated that bisphosphonates modulate osteoclast function by interacting with a cell surface receptor or an intracellular enzyme.⁷

Despite the uncertainty regarding the exact mechanism of action of the bisphosphonates, their role in decreasing osteoclast-mediated lysis of bone has been well established in clinical trials.^{1,8} The efficacy of these agents in reducing bone pain, hypercalcemia, and skeletal complications has been extensively documented in patients with advanced breast cancer and multiple myeloma.⁹⁻¹² Thus bisphosphonates are frequently administered to patients with osteolytic metastases, especially if there is risk for significant morbidity. Based on clinical practice guidelines established by the American Society of Clinical Oncology, the use of bisphosphonates is considered the standard of care for treatment of 1) moderate to severe hypercalcemia associated with malignancy and 2) metastatic osteolytic lesions associated with breast cancer and multiple myeloma in conjunction with antineoplastic chemotherapeutic agents.^{13,14} More recently, the indication for bisphosphonate treatment was broadened to include osteolytic lesions arising from any solid tumor. This has resulted in a rampant use of these bisphosphonates in most medical oncology practices within the past several years.

Pamidronate, a first-generation bisphosphonate, is administered intravenously over a 2- to 24-hour period every 3 to 4 weeks at a dose of 90 mg. Zoledronic acid, the most potent bisphosphonate in clinical use, is the next-generation bisphosphonate that was recently approved for patients with metastatic breast cancer, multiple myeloma, hypercalcemia of malignancy, or Paget's disease of bone and for patients with documented bone metastases from any solid tumor (ie, prostate cancer, lung cancer). In comparison with pamidronate, zoledronic acid was significantly more effective in controlling hypercalcemia of malignancy and reducing the overall number of skeletal-related events.¹⁵ Zoledronic acid is administered as a monthly infusion at a dose of 4 mg over a period of 15 minutes. If tolerated, it is not uncommon for these patients to be maintained on bisphosphonate therapy indefinitely. The oral bisphosphonate preparations (alendronate, risedronate) are also po-

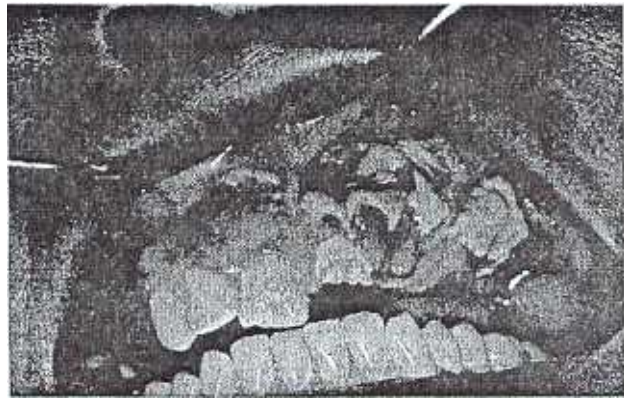


FIGURE 1. Exposed necrotic maxillary bone in a patient receiving zoledronic acid for 6 months. The patient had posterior maxillary extractions performed 4 months earlier. (Courtesy of Dr Jay Neugarten, New Hyde Park, NY.)

tent osteoclast inhibitors, but they are not as efficacious in the treatment of malignant osteolytic disease and therefore are indicated only for the treatment of osteoporosis.

At the oral and maxillofacial surgery departments of our centers, we noted a growing number of patients referred for evaluation and management of "refractory osteomyelitis" of varying duration. The typical presentation was a "nonhealing" extraction socket or exposed jawbone with progression to sequestrum formation associated with localized swelling and purulent discharge. Up to this point, this rare clinical scenario was seen only at our centers in patients who had received radiation therapy and accounted for 1 or 2 cases per year. The lesions were refractory to conservative debridement procedures and antibiotic therapy (Fig 1). All involved sites had previously undergone biopsy to rule out metastatic disease. Despite clinical and radiographic similarities to osteoradionecrosis, none of the patients had received radiation therapy to the region surrounding the jawbones. Seven of the 63 patients had a diagnosis of osteoporosis with no history of malignancy. All other affected patients had a history of one of the following malignant diseases: breast cancer, multiple myeloma, prostate cancer, lung cancer, uterine leiomyosarcoma, plasmacytoma, and leukemia (Fig 2). All patients had radiographic or nuclear scan evidence of metastatic osteolytic bone lesions. All were actively receiving chemotherapy. The individual chemotherapeutic regimens varied widely in accordance with tumor type and character. However, all patients were receiving infusions of either pamidronate or zoledronic acid at monthly intervals (Fig 3). The duration of the bisphosphonate therapy at presentation ranged from 6 to 48 months. Fourteen patients studied had received pamidronate and had been subsequently switched to zoledronic acid.

AREDIA
OMETA

1995
• Open socket
• Periodontic involvement

56

↑ ↑
FOSSAMAX ?

→ diagnostic tool

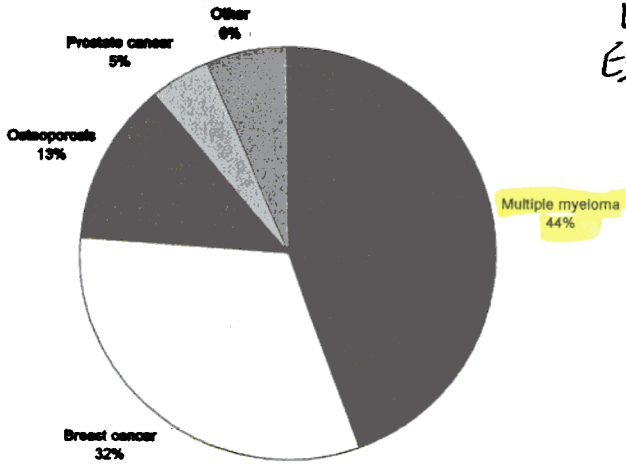


FIGURE 2. Spectrum of diagnoses associated with exposed bone (n = 63).

Patients and Methods

In accordance with the office of the Institutional Review Board, a chart review was performed on all oncology patients who presented with a diagnosis of osteonecrosis or osteomyelitis of the jaw. Patients who had a prior history of radiation therapy to the jaw region or neoplastic disease that directly involved the jaws were excluded from the review.

Results

From February 2001 through June 2003, a total of 63 patient charts from Long Island Jewish Medical Center and The University of Maryland were identified and reviewed (Table 1). There were 45 female patients and 18 male patients ranging in age from 43 to 89 years (mean age, 62 years). The most common oncologic diagnoses at presentation were multiple myeloma (28 patients) and breast cancer (20 patients), followed by prostate cancer (3 patients), lung cancer (1 patient), uterine leiomyosarcoma (1 patient), plasmacytoma (1 patient), and leukemia (1 patient). Seven patients with a diagnosis of osteoporosis were taking bisphosphonates and had no history of malignant disease or chemotherapy exposure (patients 35-37, 40, 46, 47, and 56). Twenty-four patients (38%) presented with maxillary bone involvement (19 unilateral and 5 bilateral) and 40 (63%) had mandibular bone involvement (37 unilateral and 3 bilateral). Patient 15 presented with exposed and necrotic bone in all 4 quadrants. The typical presenting symptoms were pain and exposed bone at the site of a previous tooth extraction. However, 9 of the 63 patients (14%) had had no history of a recent dentoalveolar procedure and nevertheless presented with spontaneous exposure and necrosis of the alveolar bone. Radiographs routinely showed regions of mottled bone.

diagnose symptoms → ENI
 not sources & triggers → ENI
 exposed bone thru gum → ENI
 consistent with sequestrum formation (Figs 4, 5).
 Chronic maxillary sinusitis secondary to necrotic bone and an oroantral fistula were evident in several patients with posterior maxillary involvement (patients 2, 3, 5, 13, and 17). On microscopic examination, all of the specimens consisted of necrotic bone with associated bacterial debris and granulation tissue (Fig 6). Culture results consistently revealed normal oral flora. Six patients had radiographic signs of osteolysis before the extraction of teeth, which suggested involvement of the alveolar bone before extraction.

MANAGEMENT

Minor debridement procedures under local anesthesia were attempted; however, a majority of the patients required surgical procedures to remove all of the involved bone. The procedures included 45 sequestrectomies, 4 marginal mandibular resections, 6 segmental mandibular resections, 5 partial maxillectomies, and 1 complete maxillectomy. Patients 1 and 2 received hyperbaric oxygen therapy (30 one-hour sessions) before undergoing a marginal mandibular resection of necrotic bone. However, despite the presence of vascularized bone at the resection margins, there has been progressive necrosis that will likely necessitate a segmental resection. Patients who showed regions of exposed and necrotic bone but were asymptomatic have been followed and treated conservatively with local wound care and irrigations. One patient with metastatic uterine leiomyosarcoma presented with a large sequestered segment of the right maxilla that had spontaneously exfoliated, resulting in a large oroantral communication. The cessation of bisphosphonate treatment has not had a major impact on the progression of this process. Five patients had persistent bone necrosis and even developed new regions of exposed bone despite being removed from bisphosphonate therapy by their oncologists.

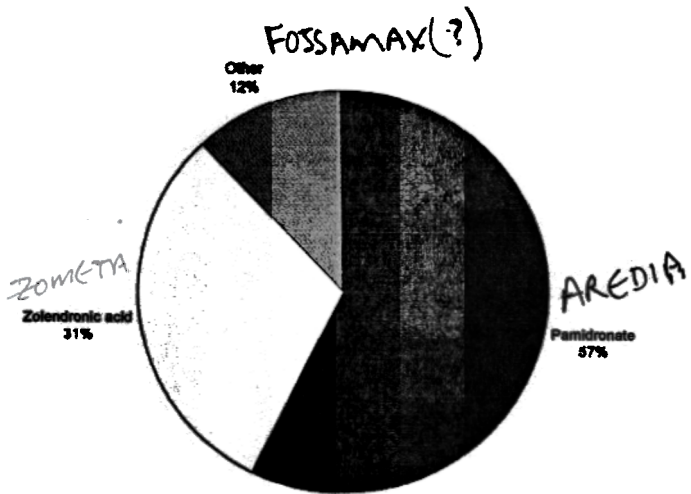


FIGURE 3. Profile of bisphosphonate use within patient group.

ask Dr. C what this means? include do me?

unilateral = top?
 bilateral = bottom?

through gum exposure?

diagnostic tool

ask Dr. C

= Photomicrograph(?)
 p. 532

Table 1. PATIENT DATA

Patient No.	Gender	Age (yr)	Diagnosis	Bisphosphonate	Site of Necrosis	Treatment
1	F	69	Breast cancer		Mandible	HBO, Marginal mandibulectomy
2	F	65	Breast cancer	Pamidronate	Mandible	Sequestrectomy
3	F	62	Breast cancer	Zoledronate	Maxilla (bilateral)	Total maxillectomy
4	F	81	Breast cancer	Pamidronate	Mandible (pathologic fracture)	Segmental mandibulectomy
5	F	62	Breast cancer	Pamidronate	Mandible	Marginal mandibulectomy
6	F	66	Breast cancer	Pamidronate	Bilateral mandible	Sequestrectomy
7	F	63	Breast cancer	Pamidronate	Maxilla	Partial maxillectomy
8	F	56	Breast cancer	Pamidronate	Mandible	Segmental mandibulectomy
9	F	66	Breast cancer	Pamidronate	Mandible (pathologic fracture)	Sequestrectomy
10	F	73	Breast cancer	Pamidronate, Zoledronate	Maxilla	Partial maxillectomy
11	F	45	Breast cancer	Pamidronate	Bilateral maxilla	Partial maxillectomy
12	F	57	Multiple myeloma	Pamidronate, Zoledronate	Mandible	Sequestrectomy (x3), segmental mandibulectomy
13	F	59	Multiple myeloma	Pamidronate	Maxilla	Partial maxillectomy
14	M	75	Multiple myeloma	Pamidronate	Mandible (pathologic fracture)	Segmental mandibulectomy
15	F	70	Multiple myeloma	Pamidronate	Bilateral maxilla and mandible (pathologic fracture)	Multiple sequestrectomies, segmental mandibulectomy
16	F	71	Multiple myeloma	Pamidronate	Mandible	Sequestrectomy
17	M	65	Multiple myeloma	Pamidronate	Mandible	Sequestrectomy, segmental mandibulectomy
18	F	69	Multiple myeloma	Pamidronate	Mandible (pathologic fracture)	Segmental mandibulectomy
19	M	58	Multiple myeloma	Pamidronate, Zoledronate	Mandible	Marginal mandibulectomy
20	F	79	Multiple myeloma	Pamidronate	Mandible	Conservative management
21	F	71	Multiple myeloma BMT	Pamidronate	Maxilla	Conservative management
22	F	58	Multiple myeloma	Pamidronate, Zoledronate	Maxilla	Partial maxillectomy
23	M	63	Lung cancer	Pamidronate	Maxilla	Sequestrectomy
24	M	80	Prostate cancer	Pamidronate	Bilateral maxilla	Sequestrectomy
25	F	80	Uterine sarcoma	Pamidronate	Maxilla	Partial maxillectomy (spontaneous)
26	M	47	CML BMT	Pamidronate	Mandible	Sequestrectomy
27	F	76	Breast cancer	Pamidronate	Mandible	Sequestrectomy
28	M	76	Prostate cancer	Pamidronate	Maxilla	Sequestrectomy
29	M	58	Multiple myeloma	Pamidronate	Maxilla	Sequestrectomy
30	F	43	Breast cancer	Pamidronate, Zoledronic acid	Mandible	Sequestrectomy
31	M	78	Prostate cancer	Pamidronate	Mandible	Sequestrectomy
32	M	70	Multiple myeloma	Pamidronate	Mandible	Sequestrectomy
33	M	78	Multiple myeloma	Pamidronate	Maxilla	Sequestrectomy
34	M	85	Multiple myeloma	Zoledronic acid	Mandible	Sequestrectomy
35	F	77	Osteoporosis	Alendronate	Bilateral mandible	Sequestrectomy
36	F	82	Osteoporosis	Alendronate	Maxilla	Sequestrectomy
37	F	80	Osteoporosis	Risedronate	Mandible	Sequestrectomy
38	M	55	Multiple myeloma	Pamidronate	Mandible	Sequestrectomy
39	F	87	Multiple myeloma	Pamidronate, Zoledronic acid	Mandible	Sequestrectomy
40	M	72	Osteoporosis	Alendronate, Zoledronic acid	Mandible	Sequestrectomy

Table 1. PATIENT DATA (Cont'd)

Patient No.	Gender	Age (yr)	Diagnosis	Bisphosphonate	Site of Necrosis	Treatment
41	M	79	Multiple myeloma	Pamidronate, Zoledronic acid	Mandible	Sequestrectomy
42	M	66	Multiple myeloma	Pamidronate, Zoledronic acid	Mandible	Sequestrectomy
43	M	80	Multiple myeloma	Pamidronate, Zoledronic acid	Maxilla	Sequestrectomy
44	M	68	Multiple myeloma	Zoledronic acid	Mandible	Sequestrectomy
45	M	68	Multiple myeloma	Pamidronate, Zoledronic acid	Mandible	Sequestrectomy
46	F	59	Osteoporosis	Alendronate	Mandible	Sequestrectomy
47	F	60	Osteoporosis	Alendronate	Mandible	Sequestrectomy
48	F	56	Breast cancer	Pamidronate	Mandible	Sequestrectomy
49	F	89	Breast cancer	Pamidronate	Maxilla	Sequestrectomy
50	F	76	Multiple myeloma	Pamidronate	Mandibular	Sequestrectomy
51	F	43	Breast cancer	Zoledronic acid	Maxilla	Sequestrectomy
52	F	79	Breast cancer	Zoledronic acid	Maxilla	Sequestrectomy
53	F	82	Breast cancer	Zoledronic acid	Maxilla	Sequestrectomy
54	M	60	Multiple myeloma	Pamidronate, Zoledronic acid	Maxilla	Sequestrectomy
55	F	52	Breast cancer	Zoledronic acid	Maxilla	Sequestrectomy
56	F	68	Osteoporosis	Alendronate	Mandible	Sequestrectomy
57	M	73	Multiple myeloma	Zoledronic acid	Maxilla	Sequestrectomy
58	M	69	Multiple myeloma	Zoledronic acid	Mandible	Sequestrectomy
59	F	74	Multiple myeloma	Pamidronate	Mandible	Sequestrectomy
60	M	70	Multiple myeloma	Pamidronate, Zoledronic acid	Mandible	Sequestrectomy
61	F	48	Breast cancer	Pamidronate, Zoledronic acid	Mandible	Sequestrectomy
62	M	56	Plasmacytoma	Pamidronate	Maxilla	Sequestrectomy
63	F	58	Breast cancer	Pamidronate	Mandible	Sequestrectomy

Abbreviations: BMT, bone marrow transplant; CML, chronic myelogenous leukemia.

Discussion

Based on these patients' respective histories, clinical presentations, and responses to surgical and antibiotic treatments, it appears that the pathogenesis of this osteonecrotic process is most consistent with localized vascular insufficiency. The lesion's clinical similarity to osteoradionecrosis, with compromised bone that sequesters either spontaneously or after a minor procedure, followed by secondary infection, is

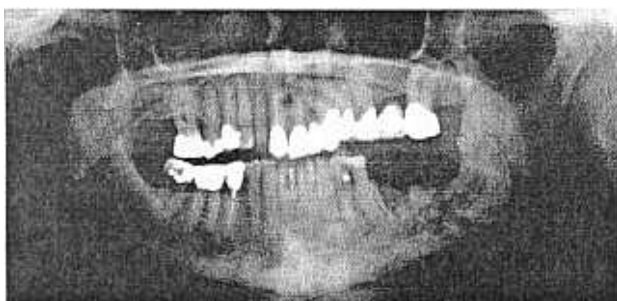

FIGURE 4. Panoramic radiograph of the mandible following extractions of left posterior teeth in a patient receiving pamidronate. The image shows the mottled bone in the region of the nonhealing extraction sites.

striking. The incidence of osteonecrosis in our patient population who are not receiving bisphosphonates remains exceedingly low. In the past 3 years, only 4 patients had a similar clinical presentation. Three of

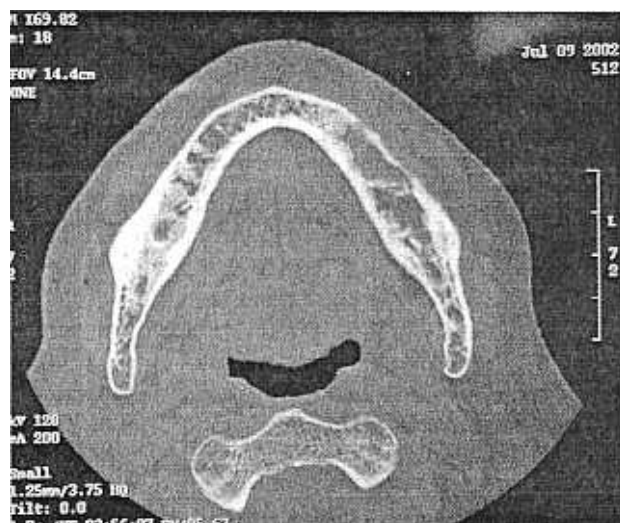


FIGURE 5. Axial computed tomography scan of the mandible of patient in Figure 2 showing regions of mottled bone and sequestrum.

(ask FASSAS)

Results in heart problems ← possible symptom

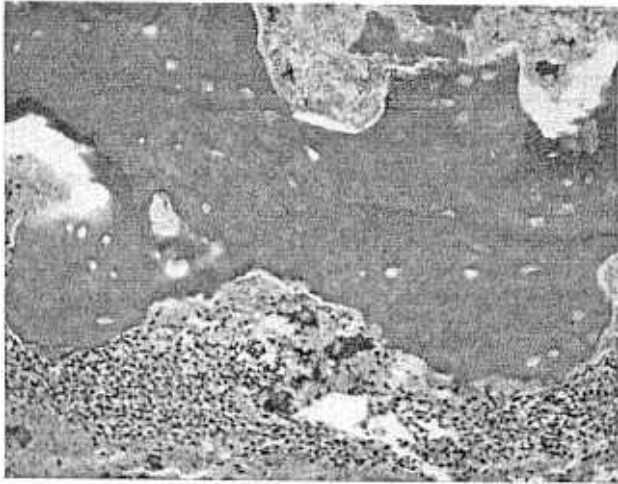


FIGURE 6. Photomicrograph of necrotic bone shows empty lacunae. Sequestrum is surrounded by neutrophils and bacterial debris (hematoxylin and eosin stain, original magnification $\times 100$).

these patients had prior radiation therapy for treatment of squamous carcinoma, and 1 patient had a diagnosis of florid osseous dysplasia. The relatively high percentage of cases with clinical involvement of the maxilla (24 of 63 patients) is unusual given that site's inherently rich vascular supply. In our opinion, the mechanism by which bisphosphonates could compromise bone vascularity may be related to its effect on the osteoclasts. The potent bisphosphonate-mediated inhibition of osteoclast function serves to decrease bone resorption and inhibit normal bone turnover remodeling, resulting in microdamage accumulation and a reduction in some mechanical properties of bone.¹⁶ However, bone resorption and remodeling play an essential role in maintaining normal bone homeostasis. As osteoclasts occur, there are a host of cytokines and growth factors released into the surrounding matrix that are essential for modulating new bone development. The inhibition of new bone formation can affect the quality of bone during growth and fracture healing. Metaphyseal sclerotic banding is a documented effect of periodic bisphosphonate treatment in growing children.^{17,18} Whyte et al¹⁹ reported a case of osteopetrosis that developed in a child receiving high-dose pamidronate over a 2-year period, where it was noted that endochondral bone was not remodeled and became encased within trabecular bone. In fracture repair, the bisphosphonate-mediated inhibition of bone remodeling results in a more profound and larger callus with no compromise in mechanical integrity.²⁰⁻²² Bisphosphonates also have shown effects unrelated to osteoclast inhibition. Pamidronate has been associated with an acute phase reaction characterized by fever and transient changes in various cytokine levels such as interleukin-6, tumor necrosis factor- α , C-reactive protein, and elastase.²³

BISPHOSPHONATES AND OSTEONECROSIS OF THE JAWS

More important, pamidronate was reported to significantly depress bone blood flow in rats.^{24,25} The mechanism of this effect may be attributable to a complex interaction of pamidronate with growth hormone and insulin-like growth factor I, both of which are thought to play a role in the regulation of blood circulation in bones. In a recent study, bisphosphonates were shown to inhibit endothelial cell function in vitro and in vivo.²⁶ Those cells treated with bisphosphonates showed decreased proliferation, an increased rate of apoptosis, and a decrease in capillary-tube formation.²⁶ In that same study, there was a marked reduction in the number of blood vessels in pagetic bone marrow after bisphosphonate treatment compared with pretreatment biopsy results. Bisphosphonates have also shown potent antiangiogenic properties due to their ability to significantly decrease circulating levels of vascular endothelial growth factor (a potent angiogenic factor) in breast cancer patients with bone metastases.²⁷ Wood et al²⁸ showed the antiangiogenic properties of bisphosphonates on several levels: 1) potent inhibitor of vessel sprouting in a chick embryo model and 2) potent inhibition of angiogenesis induced by subcutaneous implants impregnated with basic fibroblast growth factor in a murine model. These previously unrecognized antiangiogenic properties have generated interest in using bisphosphonates as potential antitumor agents.²⁹ Furthermore, these bisphosphonate properties could explain the apparent ischemic changes noted in our patients' mandibles and maxillas. These complications were not recognized during the trial stages of these drugs. This suggests that the ischemic effects may be cumulative in nature. The apparent selective involvement of the maxilla and mandible in these patients may be a reflection of the unique environment of the oral cavity. Typically, healing of an open bony wound (eg, extraction socket) in the presence of oral microflora occurs quickly and without infection. However, when the vascular supply of the mandible or maxilla is compromised by either radiation therapy or some other agent(s), then minor injury or disease in these sites is much more likely to develop into a nonhealing wound. That in turn can progress to widespread necrosis and osteomyelitis. Unlike patients with osteoradionecrosis, necrosis of the maxilla was common in bisphosphonate patients (38%) despite the inherently rich vascular supply of the maxilla. If, however, a blood-borne agent was responsible for the bone necrosis, the maxilla would certainly be at risk of developing disease, given the vascularity of the maxilla and its potential for increased exposure. The chemotherapeutic agents and steroid preparations taken by these patients can also affect wound healing and also must be considered as a possible etiologic factor. Another consideration is that these

Symptom: Count FASSAS WAS CONCERNED WITH (report to FASSAS + DR. ESCOBAR)

chemotherapy agents act synergistically with bisphosphonates to promote bone necrosis. Despite these uncertainties in the underlying mechanisms, the temporal relationship of bisphosphonate treatment with the subsequent development of osteonecrosis becomes abundantly clear. Bisphosphonate treatment was the only common factor across all 63 patients. Moreover, 7 patients in this series receiving treatment for osteoporosis were taking bisphosphonates and had no history of malignant disease or exposure to chemotherapy.

The management of these patients with bisphosphonate-related osteonecrosis remains extremely difficult. Surgical debridements have not been completely effective in eradicating the necrotic bone and hyperbaric oxygen therapy has not been uniformly effective in limiting the progression of this process. It was often difficult, if not impossible, to obtain a surgical margin with viable bleeding bone. Therefore surgical treatment should be reserved for those patients who are symptomatic. Regions of necrotic bone that are a constant source of infection and are not responsive to irrigations and antibiotic therapy should be removed. However, it is likely that the margin of the debridement will remain exposed. Symptomatic patients with pathologic mandibular fractures often require a segmental resection with a continuity defect and might require immediate reconstruction with a rigid plate. Reconstruction with free or vascularized bone and soft tissue grafts is not feasible given the likelihood that necrotic bone will be present or develop at the resection margin. Most patients with limited regions of exposed bone have been successfully managed with irrigations and antibiotic therapy.

The effect of bisphosphonates on dental implant osseointegration is unclear. In the ovariectomized rat model, Narai and Nagahata³⁰ reported that titanium implants placed in the femur of osteoporotic animals receiving alendronate had higher removal torque values than those animals who were not receiving bisphosphonate. However, dental implant failures attributable to oral bisphosphonate therapy have been reported in patients with osteoporosis.³¹ The short- and long-term effects of bisphosphonates on dental implant osseointegration need to be established for those patients receiving the more potent bisphosphonates such as pamidronate and zoledronic acid. In light of these findings, clinicians should be aware of the potential for implant failure and delayed wound healing, especially in patients receiving intravenous bisphosphonates for malignant disease.

It has been well established that bisphosphonates are extremely effective in reducing the symptoms and complications of metastatic bone disease. Consequently, these drugs have had a profound impact on the quality of life for these patients. However, the jaw

complications presented in this review have had a major negative effect on the quality of daily life for each of these patients. Although the etiology of this osteonecrotic process remains unclear, from our observations it does appear that bisphosphonates may be at least partially responsible. Because pamidronate and now zoledronic acid have become standard regimens for patients with breast cancer and multiple myeloma, awareness of this complication and its clinical significance is critical. At present, the potential relationship between bisphosphonates and osteonecrosis of the jaw remains unreported in refereed journals. There is emerging evidence from clinical observations and early clinical trials suggesting that adjuvant bisphosphonate treatment may have antitumor activity.³² This would, in effect, broaden the indications for their use in the near future. Moreover, the prevalence of this potential complication is significant because most of the affected patients had jaw disease that was not detected by their medical oncologists. The diagnosis in each case was established only after the patient presented for a dental consultation. It is important therefore that the medical community, and specifically the medical oncologist, become aware of this potential complication because such a large and growing number of their patients require bisphosphonate therapy. Similar to those patients who require head and neck radiation treatment, a complete dental evaluation should be performed before commencing bisphosphonate treatment to identify and address any dental pathology.

Although this report serves to alert clinicians about the potential complication of bone necrosis in patients receiving bisphosphonate therapy, many questions remain concerning the underlying pathogenesis of this process. Further research is needed to elucidate the precise relationship between bisphosphonates and osteonecrosis.

Acknowledgments

The authors would like to thank Dr Kanti Rai, Dr John Fantasia, Dr Ronald Burakoff, and Dale Janson, RPAC, for their assistance and support in preparation of the manuscript.

References

1. Hortobagyi GN, Theriault RL, Lipton A, et al: Long-term prevention of skeletal complications of metastatic breast cancer with pamidronate. *J Clin Oncol* 16:2038, 1998
2. Conte PF, Giannesi PG, Latreille J, et al: Delayed progression of bone metastases with pamidronate therapy in breast cancer patients: A randomized multicenter phase III trial. *Ann Oncol* 5:S41, 1994 (suppl 7)
3. Rodan GA, Fleisch HA: Bisphosphonates: Mechanisms of action. *J Clin Invest* 97:2692, 1996
4. Hughes DE, MacDonald BR, Russell RGG, et al: Inhibition of osteoclast-like cell formation by bisphosphonates in long-term cultures of human bone marrow. *J Clin Invest* 83:1930, 1989

for
P.R.C
treat-
ments
treat-
ments
treat-
ments

no
periodontals
+
no tooth
removal
implant-
ex
wisdom
teeth

5. Hughes DE, Wright KR, Uy HL, et al: Bisphosphonates promote apoptosis in murine osteoclasts *in vitro* and *in vivo*. *J Bone Miner Res* 10:1478, 1995
6. Murakami H, Takahashi N, Sasaki T, et al: A possible mechanism of the specific action of bisphosphonates on osteoclasts: Tiludronate preferentially affects polarized osteoclasts having ruffled borders. *Bone* 17:137, 1995
7. Sahni M, Guenther HL, Fleisch H, et al: Bisphosphonates act on rat bone resorption through the mediation of osteoclasts. *J Clin Invest* 91:2004, 1993
8. van Holten-Verzantvoort ATM, Kroon HM, Bijvoet OLM, et al: Palliative pamidronate treatment in patients with bone metastases from breast cancer. *J Clin Oncol* 11:491, 1993
9. Berensen JR, Lichtenstein A, Porter L, et al: Long term pamidronate treatment of advanced multiple myeloma patients reduces skeletal events. *J Clin Oncol* 16:593, 1998
10. Hortobagyi GN, Theriault RL, Porter L, et al: Efficacy of pamidronate in reducing skeletal complications in patients with breast cancer and lytic bone metastasis. *N Engl J Med* 335:1785, 1996
11. Berensen JR, Lichtenstein A, Porter L, et al: Efficacy of pamidronate in reducing skeletal events in patients with advanced multiple myeloma. *N Engl J Med* 334:448, 1996
12. Theriault RL, Lipton A, Hortobagyi ON, et al: Pamidronate reduces skeletal morbidity in women with advanced breast cancer and lytic lesions: A randomized placebo-controlled trial. *J Clin Oncol* 17:846, 1999
13. Hillner BE, Ingle JN, Berenson JR, et al: American Society of Clinical Oncology guideline on the role of bisphosphonates in breast cancer. *J Clin Oncol* 18:1378, 2000
14. Berenson JR, Hillner BE, Kyle RA, et al: American Society of Clinical Oncology clinical practice guidelines: The role of bisphosphonates in multiple myeloma. *J Clin Oncol* 20:3719, 2002
15. Coleman RE: Optimizing treatment of bone metastases by Are-dia[®] and Zometa[®]. *Breast Cancer* 7:361, 2000
16. Mashiba T, Hirano T, Turner CH, et al: Suppressed bone turnover by bisphosphonates increases microdamage accumulation and reduces some biomechanical properties in dog rib. *J Bone Miner Res* 5:613, 2001
17. Brumsen C, Hamdy NA, Papapoulos SE: Long-term effects of bisphosphonates on the growing skeleton: Studies of young patients with severe osteoporosis. *Medicine* 76:266, 1997
18. Glorieux FH, Bishop NJ, Plotkin H, et al: Cyclic administration of pamidronate in children with severe osteogenesis imperfecta. *N Engl J Med* 339:947, 1998
19. Whyte MP, Wenkert D, Clements KL, et al: Bisphosphonate-induced osteopetrosis. *N Engl J Med* 349:457, 2003
20. Goodship AE, Walker PC, McNally D, et al: Use of a bisphosphonate (pamidronate) to modulate fracture repair in ovine bone. *Ann Oncol* 5:553, 1994 (suppl 7)
21. Cao Y, Mori S, Mashiba T, et al: Raloxifene, estrogen and alendronate affect the processes of fracture repair differently in ovariectomized rats. *J Bone Miner Res* 17:2237, 2002
22. Li J, Mori S, Kaji Y, et al: Effect of bisphosphonate (incadronate) on fracture healing of long bones in rats. *J Bone Miner Res* 14:969, 1999
23. Thiebaud HD, Sauty A, Burckhardt P, et al: An *in vitro* and *in vivo* study of cytokines in the acute-phase response associated with bisphosphonates. *Calcif Tiss Int* 61:386, 1997
24. Kapitola J, Zak J, Lacinova Z, et al: Effect of growth hormone and pamidronate on bone blood flow, bone mineral and IGF-I levels in the rat. *Physiol Res* 49:S101, 2000 (suppl 1)
25. Kapitola J, Zak J: Effect of pamidronate on bone blood flow in oophorectomized rats. *Physiol Res* 47:237, 1998
26. Fournier P, Boissier S, Filleur S, et al: Bisphosphonates inhibit angiogenesis *in vitro* and testosterone-stimulated vascular re-growth in the ventral prostate in castrated rats. *Cancer Res* 62:6538, 2002
27. Santini D, Vincenzi B, Avvisati G, et al: Pamidronate induces modifications of circulating angiogenic factors in cancer patients. *Clin Cancer Res* 8:1080, 2002
28. Wood J, Bonjean K, Ruetz S, et al: Novel antiangiogenic effects of the bisphosphonate compound zoledronic acid. *J Pharmacol Exp Ther* 302:1055, 2002
29. Powles T, Paterson S, Kanis JA, et al: Randomized, placebo-controlled trial of clodronate in patients with primary operable breast cancer. *J Clin Oncol* 20:3219, 2002
30. Narai S, Nagahata S: Effects of alendronate on the removal torque of implants in rats with induced osteoporosis. *Int J Oral Maxillofac Implants* 18:218, 2003
31. Starck W, Epker B: Failure of osseointegrated dental implants after diphosphonate therapy for osteoporosis: A case report. *Int J Oral Maxillofac Implants* 10:74, 1995
32. DieI ID, Solomayer EF, Costa SD, et al: Reduction in new metastases in breast cancer with adjuvant clodronate treatment. *N Engl J Med* 339:357, 1998